

## Case Report

# BREAST TISSUE IN BENIGN TUMOR OF ANAL MARGIN

## TEJIDO MAMARIO EN TUMORACIÓN BENIGNA DE MARGEN ANAL

Alessandro Bianchi<sup>1\*</sup>; Aina Ochogavia Seguí<sup>1</sup>; Marina Jiménez Segovia<sup>1</sup>;  
Myriam Fernández Isart<sup>1</sup>; Alberto Pagan Pomar<sup>1</sup>; José Antonio Martínez Corcoles<sup>1</sup>;  
Jaime Bonnín Pascual<sup>1</sup>; Elias Palma Zamora<sup>1</sup>; Xavier Francesc González Argenté<sup>1</sup>.

<sup>1</sup> Department of General Surgery, Hospital Universitario Son Espases, Palma de Mallorca, Spain.

\* Corresponding author: Department of General Surgery, *Hospital Universitario Son Espases*. Ctra. De Valldemossa 79.

Balearic Islands, Palma de Mallorca, 07010. Spain. Phone: 0034-871205000.

E-mail address: aplbianchi@gmail.com

Received: 12 April 2017; Accepted: 21 September 2017; Published: February 2018.

### Abstract:

**Introduction:** Adenomas in the anogenital region are uncommon and the origin of this kind of lesion has created confusion. In the past these lesions have been considered as ectopic breast tissues or as cutaneous apocrine glands. More recently they have been defined as mammary-type anogenital glands.

**Presentation of the case:** This case reports an anogenital mass in a 47-year-old woman that was removed and subsequently studied through a pathological and immunohistochemical study. Microscopic tissue sections showed a morphologic pattern similar to that of a mammary fibroadenomas, and immunohistochemical study demonstrated the presence of oestrogen receptors and progesterone receptors. The definitive diagnosis was an apocrine adenoma tubulo-papillary without signs of malignancy.

**Conclusion:** When a tumour of the anal margin of unknown origin is found, it is opportune to consider, although very rare, the adenomas that mimic the mammary tissues.

### Resumen:

**Introducción:** Los adenomas en la región anogenital son infrecuentes y el origen de este tipo de lesión ha creado confusión. En el pasado estas lesiones se han considerado como tejidos ectópicos mamarios o como glándulas apócrina cutánea. Más recientemente han sido definidas como glándulas anogenital de tipo mamario.

**Presentación del caso:** Este caso presenta una masa anogenital de origen ectópico en una mujer de 47 años de edad. Las secciones de tejido microscópico mostraron un patrón morfológico similar al de un fibroadenomas mamario, y la inmunotinción demostró la presencia de receptores de estrógenos y receptores de progesterona. El diagnóstico definitivo fue un adenoma apócrino tubulo-papilar sin signos de malignidad.

**Conclusión:** Cuando se encuentra un tumor del margen anal de origen desconocido, es oportuno considerar, aunque muy raros, los adenomas que imitan los tejidos mamarios.

**Keywords:** Adenoma, Anus Neoplasms, Breast Neoplasms, and Breast Glands.

## Introducción

Mammary-like glands (MLGs) have been identified as a type of cutaneous adnexal gland, localized to the anogenital area of both sexes, with characteristics of modified eccrine and apocrine glands (1). Although eccrine glands develop separately from apocrine glands in embryological considerations (2), the MLGs show intermediate morphology between both, resembling the mammary glands and which have originally been termed anogenital sweat glands (3). From these tissues and these glands can form tumours, both benign and malignant. These lesions epithelial or stromal present a surprising similarity with mammary homologues (4–6). The tumours from MLGs are subject to hormone responses and may develop benign and malignant pathologic processes similar to those seen in normally located breast tissue, including fibrocystic disease, fibroadenomas, intraductales papilloma, and mucinous, ductal, and lobular carcinoma (7,8). Lesions in the anogenital area reported earlier as apocrine adenoma and apocrine fibroadenomas are likely types of adenomas of anogenital mammary-like glands (9). We describe a rare apocrine tumour in the anogenital region of a female and suggest that it is derived from female anogenital MLGs.

## Presentation of the case

A 47-year-old female patient with pathological history of idiopathic hydrocephalus went to the Emergency Department to present perianal tumour of 6 months of evolution and progressive growth without presenting typical proctologic symptomatology (Fig. 1). A clinical examination revealed a non-painful multicystic pediculate mass of about 6 cm in diameter, not bleeding and with origin at external cutaneous haemorrhoidal fold level in posterior raphe. On physical examination the rectal examination was normal, with basal sphincter tone in 4/5 and tone in contraction in 8/10. As ancillary tests, anoscopy was performed without any pathological alterations. It was operated in a programmed way. The patient was placed in Trendelenburg position with high legs. After a complete exposition of the perianal region, an exéresis of a polypoid lesion in the left-side anal margin depending on the perianal skin was performed

by using Ligasure®. The intervention was completed by reviewing haemostasis. The piece was referred to Anatomical Pathology Department for pathological study. The patient had a good postoperative course.

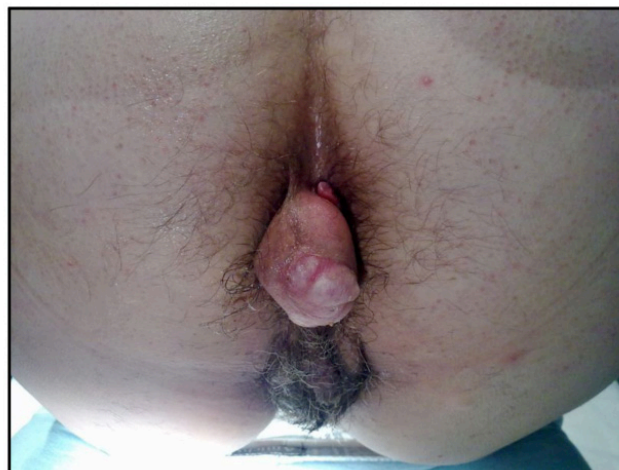

Fig. 1. Lesion object of the clinical case.

The anatomopathological study reported a dermal tumour with no connection to the epidermis, consisting of a fibroadipose stroma, showing tubular structures of different sizes coated with cuboidal epithelium of broad eosinophil cytoplasm with rounded nuclei showing apocrine decapitation and areas where the lining was more cylindrical and scarce cytoplasm. Dilated cystic lesions with secretions, epithelial areas with papillary morphology, and areas of small glands with irregular morphology with markedly sclerosed stroma coated by epithelium of similar characteristics are also observed (Fig.2). The immunohistochemical study reflected a positivity for GCDFP15, EMA, cytokeratin 7 and cytokeratin 8-18, as well as nuclear expression of oestrogen and progesterone receptors. All glandular groups present basal myoepithelial lining staining with actin staining and S100. The

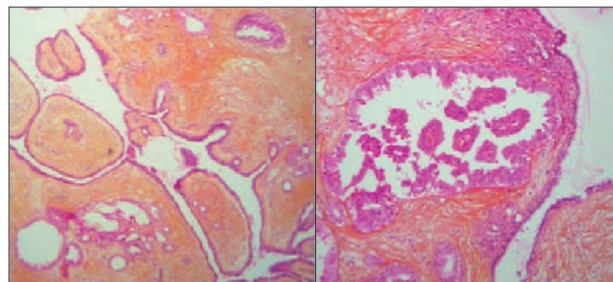


Figura 2. Microscopic vision of the lesion.

proliferation rate with Ki67 staining was less than 1%. The definitive diagnosis was of apocrine tubulopapillary adenoma without signs of malignancy.

## Discussion

Aberrant mammary tissue occurs in 1-6% of the population, being more prevalent in women in axilla and in upper umbilical scars location(10). For a long time considered as ectopic mammary-like glands, the mammary glandular tissue in the perianal region has been recognized, in the last decade, as a perianal tissue (1). MLGs have many similarities with the breast tissue itself, among them the ability to form lobules and secretory acinus. The secretory epithelium of the glands is characterized by a cylindrical epithelium identical to that found in the mammary region and has the capacity to respond to hormonal stimuli responding to oestrogen and progesterone (8,11). The prevalence and incidence of this type of lesion in the perianal region is unknown. The anogenital fibroadenoma is the most common lesion emerging during the reproductive years, mostly less than 30 years of age (80%) (12). In the case presented the patient was 47 years old. Similar cases with the same age have been described, although of different origin than anal area, such as the vulva area, armpit, etc (13). Since its description numerous injuries have been documented, including benign and malignant lesions (14). Although rare and uncommon lesions have been described fibroadenomas (15), lactose producing adenoma (16), extra-mammary Paget's disease (17,18), intraductales carcinomas (19–21), tubulolobular carcinomas and even invasive adenocarcinomas (22). As in the case presented in this paper where a pedicle lesion has subsequently been diagnosed as tubulo-papillary adenoma without signs of malignancy. The similarity between lesions of the perianal region and those originating from the mammary tissue confirm how the mammary glandular tissue of the perianal region should be considered as a tissue of the perianal region but with characteristics that are all similar with the mammary counterparts. This is demonstrated by the fact that in the lesion object of our paper were found receptors for oestrogens and progesterone.

Although the incidence of this type of lesions is low, mammary-like glands should be considered within the differential diagnosis of anogenital pathology.

The recommended treatment is excision, which turns out to be curative. The pathological confirmation is mandatory to exclude the possibility of other tumours occurrence, including malignancy. As expressed in other papers further histological research by assessment of the development of new molecular markers may need to provide new evidences to consolidate the actual concept of mammary-like gland anogenital adenomas origin within mammary-type anogenital glands.

## Conflict of interests

This work has not received funding of any kind. The authors declare that they have no conflicts of interest in carrying out the work.

## References

1. van der Putte SC. Anogenital "sweat" glands. Histology and pathology of a gland that may mimic mammary glands. *Am J Dermatopathol.* 1991 Dec;13(6):557–67.
2. Groscurth P. Anatomy of sweat glands. *Curr Probl Dermatol.* 2002;30:1–9.
3. Woodworth H, Dockerty MB, Wilson RB, Pratt JH. Papillary hidradenoma of the vulva: a clinicopathologic study of 69 cases. *Am J Obstet Gynecol.* 1971 Jun 15;110(4):501–8.
4. Baisre A, Heller DS, Lee J, Zheng P. Fibroadenoma of the vulva. A report of two cases. *J Reprod Med.* 2002 Nov;47(11):949–51.
5. Chung-Park M, Zheng Liu C, Giampoli EJ, Emery JD, Shalodi A. Mucinous adenocarcinoma of ectopic breast tissue of the vulva. *Arch Pathol Lab Med.* 2002 Oct;126(10):1216–8.
6. Irvin WP, Cathro HP, Grosh WW, Rice LW, Andersen WA. Primary breast carcinoma of the vulva: a case report and literature review. *Gynecol Oncol.* 1999 Apr;73(1):155–9.
7. Piura B, Gemer O, Rabinovich A, Yanai-Inbar I. Primary breast carcinoma of the vulva: case report and review of literature. *Eur J Gynaecol Oncol.* 2002;23(1):21–4.
8. Yin C, Chapman J, Tawfik O. Invasive mucinous (colloid) adenocarcinoma of ectopic breast tissue in the vulva: a case report. *Breast J.* 2003 Apr;9(2):113–5.
9. Assor D, Davis JB. Multiple apocrine fibroadenomas of the anal skin. *Am J Clin Pathol.* 1977 Sep;68(3):397–9.
10. Amalinei C, Giusca SE, Caruntu ID. Fibroadenomas of anogenital mammary-like glands: from embryogenesis anomaly to apocrine origin. *Pol J Pathol Off J Pol Soc Pathol.* 2015 Sep;66(3):219–23.

11. Konstantinova AM, Shelekhova KV. [Fibroepithelial tumors of the anogenital mammary-like glands]. *Arkh Patol.* 2017;79(4):40–7.
12. Plantier F, groupe de dermatopathologie de la Société française de dermatologie. [Hidradenoma papilliferum or anogenital mammary-like gland adenoma]. *Ann Dermatol Venereol.* 2015 Oct;142(10):609–12.
13. Khalsa A, Conway A, Ali L, Heaney S, Helm K. Apocrine Fibroadenoma on the Face: Case Report and Review of the Literature. *Am J Dermatopathol.* 2016 Mar;38(3):236–8.
14. Kazakov DV, Spagnolo DV, Kacerovska D, Michal M. Lesions of anogenital mammary-like glands: an update. *Adv Anat Pathol.* 2011 Jan;18(1):1–28.
15. Choi WWL, Tadros TS, Majmudar B. Anal fibroadenoma: report of a common tumor type in an unusual location. *South Med J.* 2007 Sep;100(9):914–5.
16. van der Putte SC. Mammary-like glands of the vulva and their disorders. *Int J Gynecol Pathol Off J Int Soc Gynecol Pathol.* 1994 Apr;13(2):150–60.
17. Higgins CM, Strutton GM. Papillary apocrine fibroadenoma of the vulva. *J Cutan Pathol.* 1997 Apr;24(4):256–60.
18. Konstantinova AM, Spagnolo DV, Stewart CJR, Kacerovska D, Shelekhova KV, Plaza JA, et al. Spectrum of Changes in Anogenital Mammary-like Glands in Primary Extramammary (Anogenital) Paget Disease and Their Possible Role in the Pathogenesis of the Disease. *Am J Surg Pathol.* 2017 Aug;41(8):1053–8.
19. Castro CY, Deavers M. Ductal carcinoma in-situ arising in mammary-like glands of the vulva. *Int J Gynecol Pathol Off J Int Soc Gynecol Pathol.* 2001 Jul;20(3):277–83.
20. Pelosi G, Martignoni G, Bonetti F. Intraductal carcinoma of mammary-type apocrine epithelium arising within a papillary hidradenoma of the vulva. Report of a case and review of the literature. *Arch Pathol Lab Med.* 1991 Dec;115(12):1249–54.
21. Obaidat NA, Awamleh AA, Ghazarian DM. Adenocarcinoma in situ arising in a tubulopapillary apocrine hidradenoma of the peri-anal region. *Eur J Dermatol EJD.* 2006 Oct;16(5):576–8.
22. Kazakov DV, Belousova IE, Sima R, Michal M. Mammary type tubulolobular carcinoma of the anogenital area: report of a case of a unique tumor presumably originating in anogenital mammarylike glands. *Am J Surg Pathol.* 2006 Sep;30(9):1193–6.