

Images in medicine

Schönlein-Henoch vasculitis in an adult

Vasculitis de Schönlein-Henoch en un adulto



Meritxell Gavalrà^{a,*}, Helem Vilchez^a, Pilar Salva^a, Daniel Ramos^b, Carlos Saus^c, Mercedes García^a

^a Internal Medicine, Hospital Universitari Son Espases, Palma, Mallorca, Spain

^b Dermatology, Hospital Universitari Son Espases, Palma, Mallorca, Spain

^c Pathology, Hospital Universitari Son Espases, Palma, Mallorca, Spain

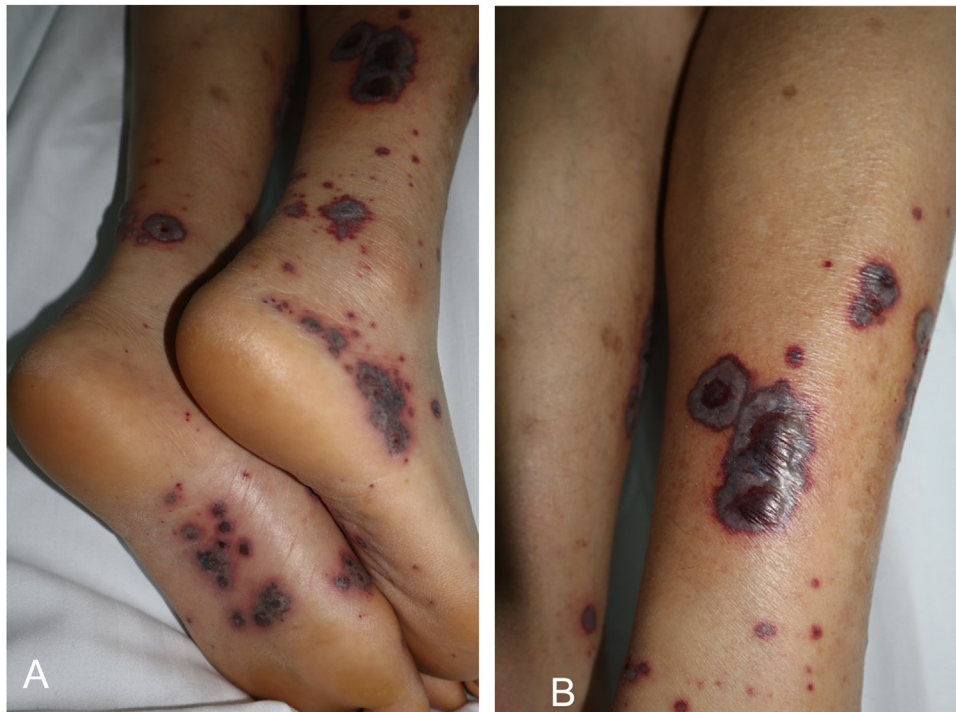

Fig. 1. Purpuric lesions on the lower limbs.

* Corresponding author.
E-mail address: meritxellgavaldamanso@gmail.com (M. Gavalrà).

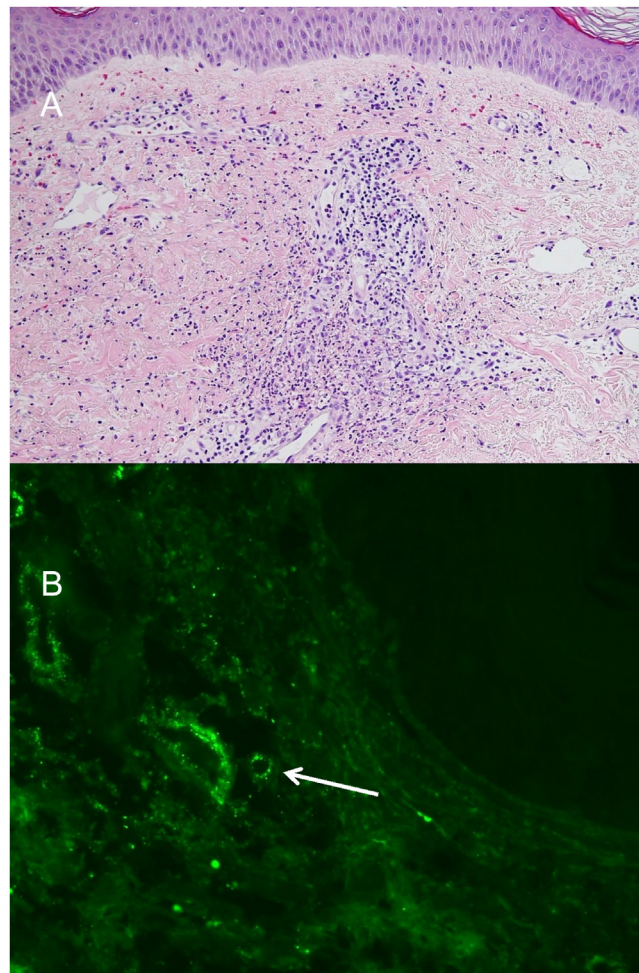


Fig. 2. A: Histological image HE x5, small base leukocytoclastic vasculitis in superficialreticular and papular dermis. B: Direct immunofluorescence testing for IgA, perivascular IgA deposits (white arrow).

A 60-year old man with medical history of dyslipidemia and gout presented with palpable purpura, haemorrhagic vesicles in the lower limbs (Fig. 1), small and large joint polyarthritits and abdominal pain without diarrhea. The cardiorespiratory and abdominal examinations were normal, no fever or oxygen desaturation was observed. Initial blood analysis showed normal values except for leukocytosis of $11.8 \times 10^3/\text{mm}^3$ with left shift and elevated C-reactive protein (12.73 mg/dl). Hemoglobin, platelets, coagulation, liver enzymes, renal function and ions were normal. The initial urine test presented proteinuria of 30 mg/dl. Chest X-ray showed a right pleural effusion. Blood cultures were negative and cardiac echocardiogram ruled out endocarditis. Human Immunodeficiency Virus, hepatitis B and C virus, Cytomegalovirus, Treponema pallidum, Varicella Zoster Virus, Erythrovirus B19, *Bartonella quintina*, *Bartonella henselae*, *Coxiella burnetii*, *Chlamydophila pneumoniae* and *Mycoplasma pneumoniae* serologies were negative. An autoimmunity study was performed (CH50, C3, CD, ANA, anticardiolipine, anti- β 2GPI antibodies, ANCA, RF and cryoglobulins) with negative results. The anatomopathological result of skin biopsy showed a small vase vasculitis with IgA deposits (Fig. 2) that confirmed the suspicion of Schönlein-Henoch disease. Due to the deterioration of the renal function, a daily dose of 40 mg of prednisone was given, with resolution of the symptoms and analytical alterations.

Conflict of interest

None.